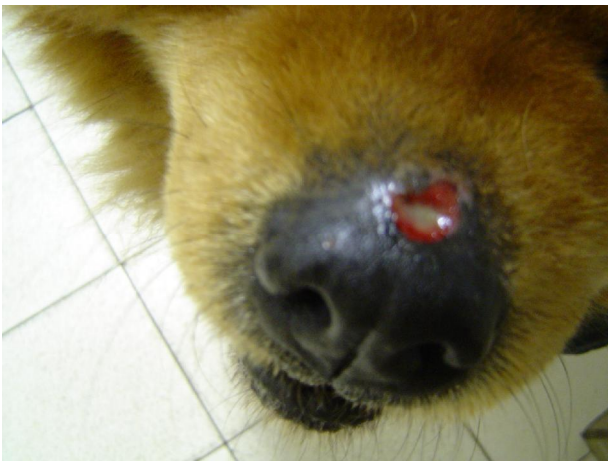

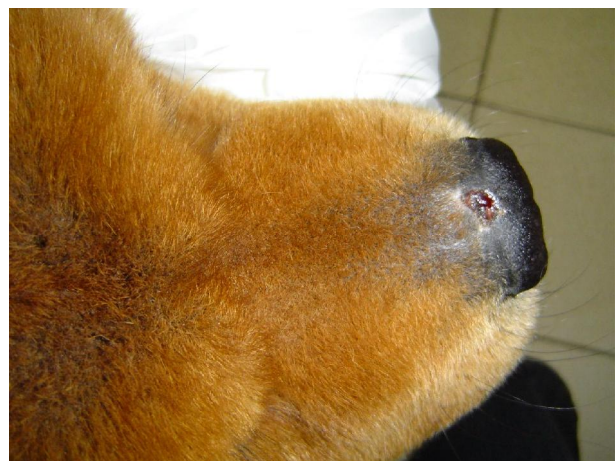
Case study:

Chronic wound on nose

- Patient:** 5 year old female Chow dog.
- History:** The patient presented with a 6 month old chronic lesion on the nose which had developed after surgical removal of a mass. The wound were not healing due to chronic licking by the patient.
- Treatment:** Light therapy was done for 5 minutes, once a day, for a week and thereafter once 3 times a week for 2 weeks. The wound took, in total, 20 days to heal completely. The patient was kept on concurrent Cephalexin antibiotics and anti-inflammatory drugs.
- Outcome:** The wound has not yet recurred to date. From the second day of light therapy the wound started to shallow, no more necrosis took place and granulation tissue started filling the defect. Due to the chronic nature of the wound, it took slightly more light therapy sessions in comparison to wounds 21 days old or less. Overall the patient had less pain, resulting in less licking of the area and the healing was process could progress faster.



Presenting lesion



2 weeks and 8 light therapy sessions later